Guidelines for MR Imaging of Sports Injuries

European Society of Skeletal Radiology
Sports Sub-committee

2016

Contributors

- Ara Kassarjian, Spain
- Lars Benjamin Fritz, Germany
- P. Diana Afonso, Portugal
- Andrea Alcalá-Galiano, Spain
- María José Ereño, Spain
- Andrew Grainger, UK
- Eva Llopis, Spain
- Eugene McNally, UK
- Claudia Schüller-Weidekamm, Austria
- Reto Sutter, Switzerland

Abbreviations and clarifications

- Ax = axial
- Cor = coronal
- Sag = sagittal
- FOV = field of view
- PD = proton density
- TE = time to echo in milliseconds
- FS = fat suppressed
- Int = intermediate
- Int FS: this is a fat suppressed sequence with a long TR and a TE between that of a traditional PD (e.g. TE= 10-20) and a traditional T2 (e.g. TE=80-100). The advantage of this sequence is that the TE is short enough to maintain sufficient signal for visualisation of the anatomy (like a PD) yet long enough to be more fluid sensitive (like a T2)
- For STIR sequence, TI (inversion time) should be 140-150 at 1.5T

Wrist

- Patient in prone position with elevated arm (‘Superman position’)
- Wrist at center of scanner, use dedicated wrist coil or small surface coil
- Coronals oriented between radial and ulnar styloid process
- Sagittals are oriented 90° to coronals
- Axials include volume 2-3 cm proximal of radiocarpal joint to 1 cm distal of the carpometacarpal joints

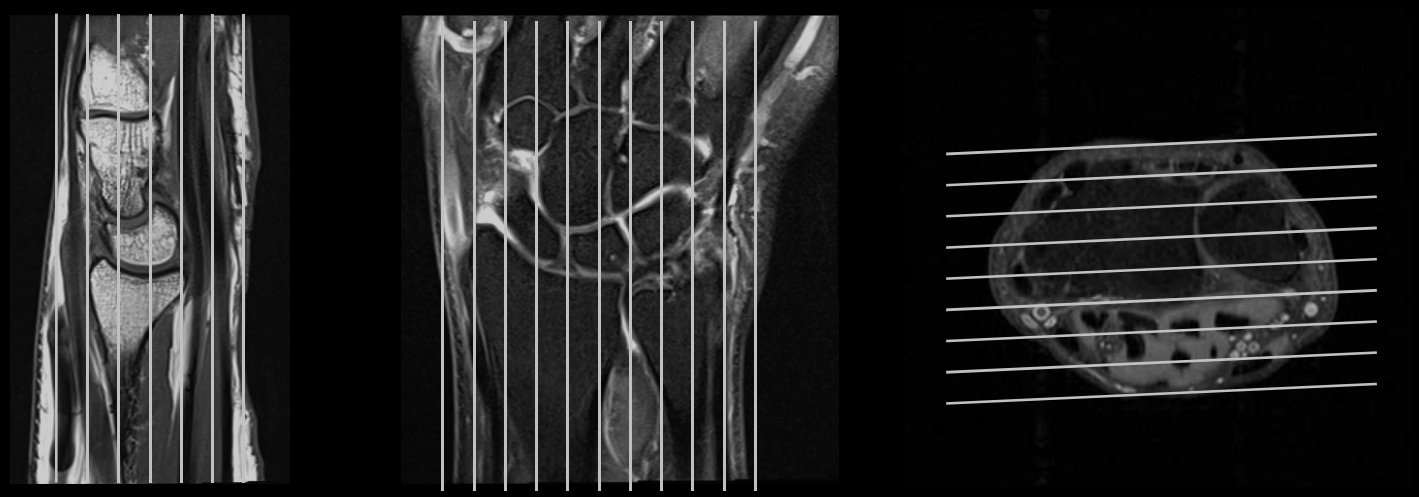

Wrist

	FOV	Slice	TE	Matrix (min)
Cor T1	8-10 cm	2-3 mm	min.	240x320
Cor PD FS	8-10 cm	2-3 mm	10-20	240x320
Cor TrueFisp 3D	10 cm	1.5-2 mm	5	320x450
Sag T1	10 cm	2-3 mm	min.	240x320
Ax PD FS	10 cm	2-3 mm	10-20	320x420
Sag PD FS	10 cm	2-3 mm	10-20	240x320

Wrist

Cor T1

Cor PD FS

Cor True Fisp 3D

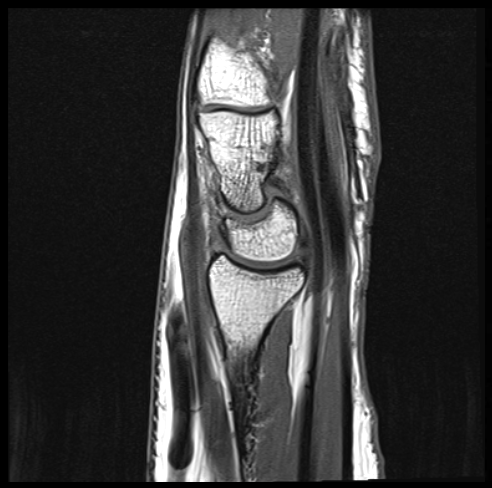

Sag T1

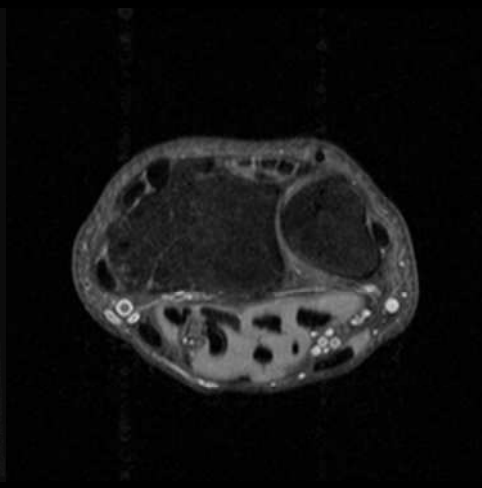

Ax PD FS

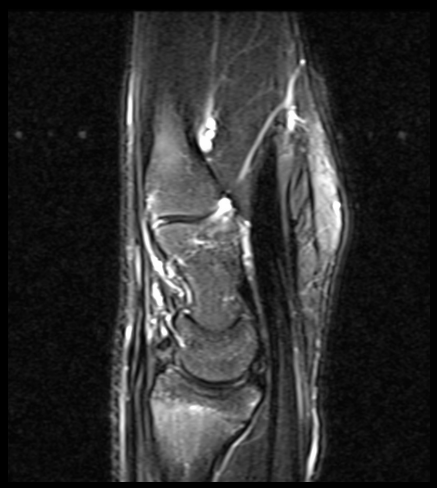

Sag PD FS