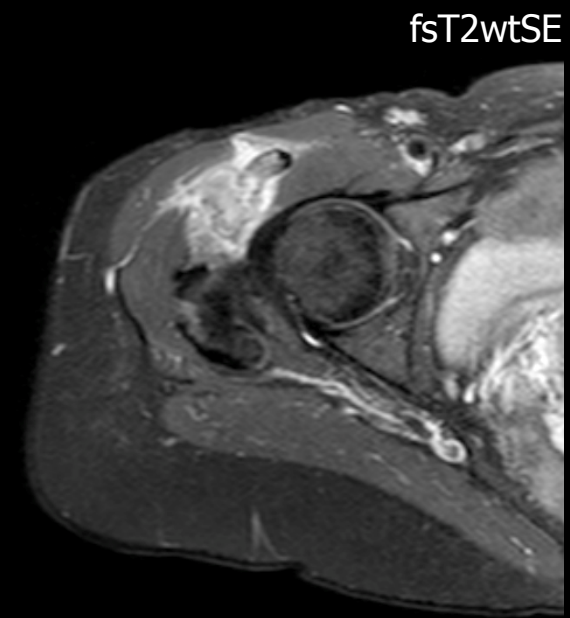
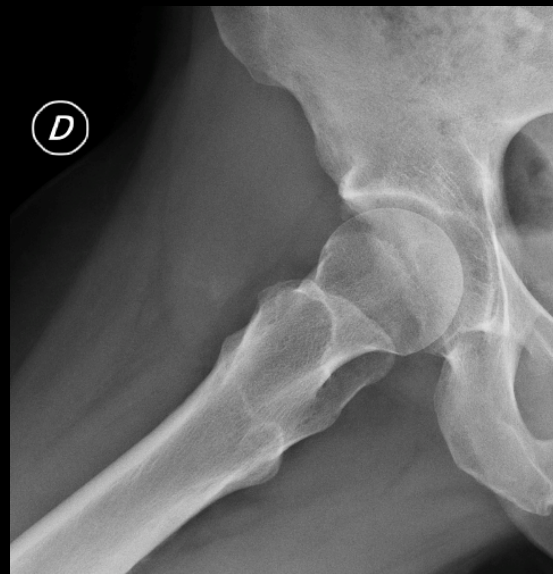
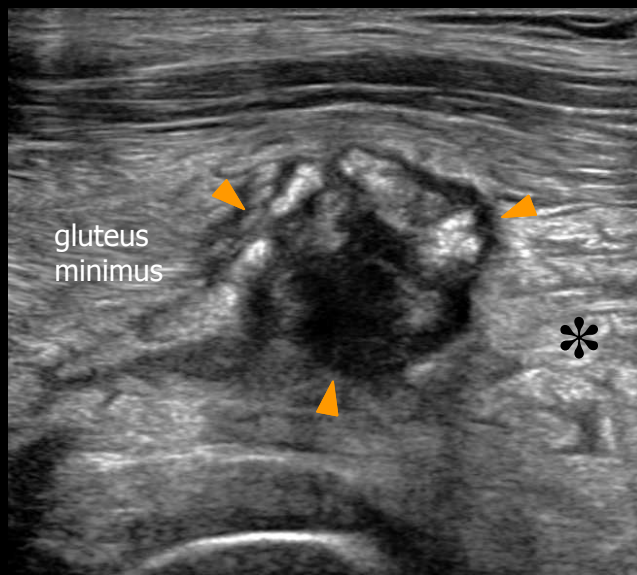


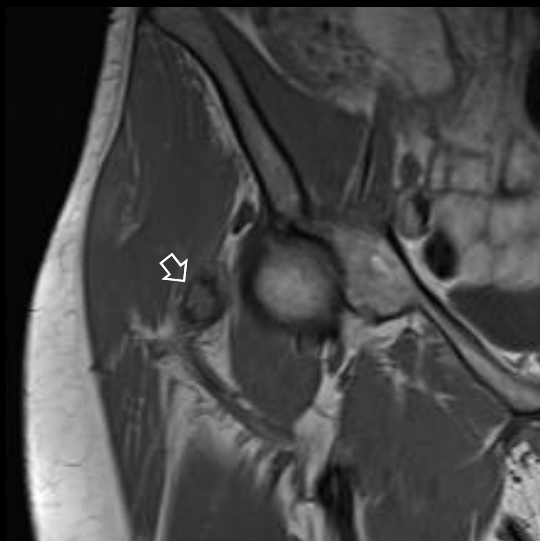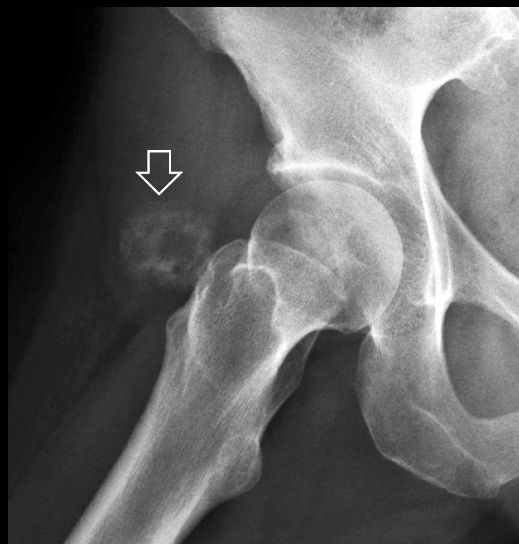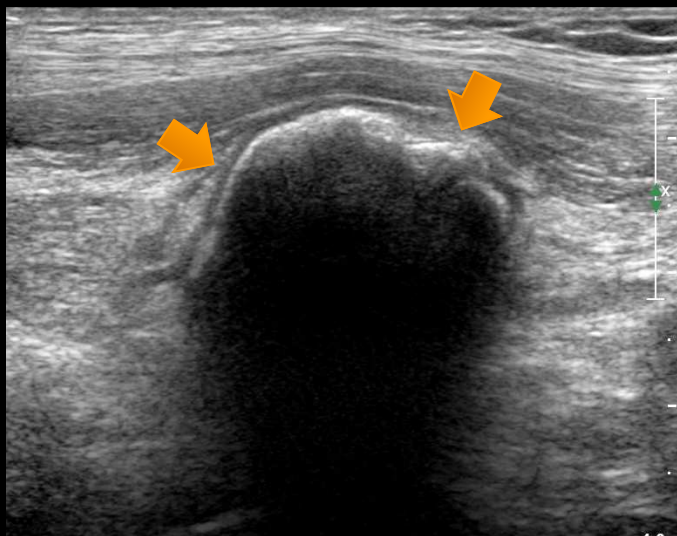ORAL EXAM

During the oral part of the exam, candidates are required to discuss relevant imaging findings and make the diagnosis. Here you can find a few images of the case that was under discussion in the last session of the ESSR Diploma. The case refers to a 45 year-old woman with recent onset of right anterolateral hip pain. Which is the diagnosis?



ORAL EXAM

The images shown below were obtained two month later ...



DIAGNOSIS

Myositis Ossificans