

# European Diploma in Musculoskeletal Radiology: Oral Part of the Exam

Marc-André Weber, MD, MSc, EDiMSK<sup>1</sup>  Mitja Rupreht, MD, PhD<sup>2,3</sup>   
 Elena Drakonaki, MD, PhD, EDiMSK<sup>4,5</sup>  Carlo Martinoli, MD, PhD<sup>6</sup>   
 Filip Vanhoenacker, MD, PhD<sup>7,8,9</sup>  Philip Robinson, MB ChB (Honors), FRCR<sup>10</sup>   
 Miraude Adriaensen, MD, PhD, MSc, EDiMSK<sup>11</sup> 

<sup>1</sup>Institute of Diagnostic and Interventional Radiology, Pediatric Radiology and Neuroradiology, University Medical Center Rostock, Rostock, Germany

<sup>2</sup>Radiology Department, University Medical Centre Maribor, Maribor, Slovenia

<sup>3</sup>Medical Faculty, University of Maribor, Maribor, Slovenia

<sup>4</sup>Department of Anatomy, University of Crete School of Medicine, Heraklion, Greece

<sup>5</sup>Department of MSK Imaging, Diagnostic and Interventional Ultrasound Practice, Heraklion, Greece

<sup>6</sup>Department of Health Sciences, University of Genoa, Genova, Italy

<sup>7</sup>Department of Radiology, Antwerp University Hospital, Edegem, Belgium

**Address for correspondence** Marc-André Weber, MD, MSc, EDiMSK, FESER, FCIIRSE, Institute of Diagnostic and Interventional Radiology, Pediatric Radiology and Neuroradiology, University Medical Center Rostock, Ernst-Heydemann-Str. 6, 18057 Rostock, Germany (e-mail: marc-andre.weber@med.uni-rostock.de).

<sup>8</sup>Department of Radiology, AZ Sint-Maarten, Mechelen, Belgium

<sup>9</sup>Faculty of Medicine and Health Sciences, Universities of Ghent and Antwerp, Belgium

<sup>10</sup>Radiology Department, Chapel Allerton Hospital, Leeds Teaching Hospitals NHS Trust, Leeds, United Kingdom

<sup>11</sup>Department of Medical Imaging, Zuyderland Medical Centre, Sittard-Geleen, Heerlen, Brunssum, Kerkrade, The Netherlands

Semin Musculoskelet Radiol

## Abstract

### Keywords

- ▶ European Society of Musculoskeletal Radiology
- ▶ diploma
- ▶ European Diploma in Musculoskeletal Radiology
- ▶ exam
- ▶ clinical cases

The European Diploma in Musculoskeletal Radiology (EDiMSK) is a recognized European qualification of excellence for musculoskeletal (MSK) radiologists. The EDiMSK confirms proof of knowledge of MSK radiology in addition to any national qualifications certifying competency. The examination is conducted in English and consists of both a written and an oral part. This article guides candidates taking the EDiMSK examination on how to prepare for the oral exam that consists of clinical cases. Information is provided on how the clinical cases are structured and how the candidate is scored. Ten cases representative of the oral section of the EDiMSK are also presented.

The European Training Curriculum for Subspecialization in Radiology (ETCSR) provides curricular contents for a full subspecialization in a field of radiology beyond year 5.<sup>1</sup> As recommended by the European Society of Radiology (ESR) and the European Union of Medical Specialists, at the end of level III training, objective measurement of the achieved standard should be made in

line with national customs and practices, and a subspecialty exam should ideally be part of the completion of training.<sup>1-3</sup> ETCSR cites 13 fields of subspecialization in radiology,<sup>1,2,4</sup> listed in Table 1 in the article in this issue that describes the written part of the European Diploma in Musculoskeletal Radiology (EDiMSK).<sup>5</sup> To our knowledge, there are not many subspe-

cialty exams and formal qualifications at the national level in musculoskeletal (MSK) radiology in Europe.<sup>6</sup>

The EDiMSK is a recognized European qualification of excellence for MSK radiologists. It serves as a tool for the standardization and accreditation of radiologists across and beyond European borders and will help regulate training across Europe.<sup>7</sup> In addition, it will

assist its holders to promote their skills and experience when dealing with other clinical colleagues, the general public, and their patients. The ESR endorses the EDiMSK for all these reasons.<sup>7</sup>

The EDiMSK provides an international benchmark for MSK radiology above general radiology. It certifies that the holder has a high level of knowledge of MSK radiology in line with the requirements of the ETCSR<sup>1</sup> by first successfully passing a written test of knowledge consisting of 40 multiple-choice questions covering all level III topics in MSK radiology, as well as the European Society of Musculoskeletal Radiology (ESSR) subcommittees area of expertise, and then taking an oral test discussing cases falling within the level III curriculum that practicing MSK radiologists can be expected to encounter in their practice.<sup>8</sup> The EDiMSK confirms proof of knowledge of MSK radiology in addition to any national qualifications certifying competency. Thus it may contribute to reinforce the candidate's curriculum vitae, helping enhance their career profile.<sup>9</sup>

Of note, the level of knowledge requested from candidates must correspond to the curricular contents for full subspecialization in the field of radiology provided by the ETCSR.<sup>1</sup> Thus all exam questions and cases primarily reflect knowledge in MSK radiology at a standard to be expected at the end of training at level III as outlined in the ETCSR. Given the fact that the ESR Level III Training Curriculum in MSK radiology actually comprises knowledge of different fields within MSK radiology, each field may be represented by a separate question and/or clinical case in the EDiMSK. The different topics of the ESR Level III Training Curriculum in MSK radiology are summarized in Table 2 in the article in this issue that describes the written part of the EDiMSK.<sup>5</sup>

Given this large range of topics, it becomes obvious why the EDiMSK examination is only open to fully trained licensed and practicing radiologists with at least 2 years of subspecialization training in MSK radiology.<sup>7</sup> A candidate who has passed the EDiMSK should be able to work as a consultant

radiologist in a hospital or private practice with a focus on MSK diseases in close collaboration with clinical colleagues.

The examination is held in English and consists of both a written and an oral part. The candidate must pass both sections of the examination.<sup>7</sup> The written part is held first, and only candidates who have successfully passed it can proceed to the oral component of the examination. The candidate obviously needs a sufficient level of competence in the English language to conduct a productive conversation with the examiners and use correct medical terms in English.

The ESSR Educational Committee frequently receives questions about how best to prepare for the EDiMSK exam. We describe what candidates can expect and how to prepare to pass the oral part of the exam. As noted earlier, detailed information on the written part of the examination is available in a separate article in this issue of the journal.<sup>5</sup> More general recommendations and the results of a survey of candidates who had successfully passed the examination were published in an earlier issue of *Seminars*.<sup>7</sup>

## Oral Part of the Examination

Each candidate is tested by three pairs of examiners assigned by the ESSR. Each pair presents a case shown at a Picture Archiving and Communication System (PACS) workstation. The candidate sits between them, with one examiner asking the questions while the other records the conversation and may also pose a specific inquiry. The total examination time planned for the three cases is 20 minutes, excluding transfers between workstations. All cases shown during the oral exam and the corresponding structured answer forms are validated and approved by an external committee of senior radiologists who have a background in MSK radiology, international higher and postgraduate education credits, and have passed specialist medical examinations.

During the oral part of the exam, candidates are required to discuss rel-

evant imaging findings and establish the diagnosis. The examiners rate whether the candidate (1) recognizes abnormalities, (2) interprets them logically, and (3) can identify the diagnosis or offer a short list of differential diagnoses. These three competences must be demonstrated to pass the oral examination.

In addition to these three tasks, the examiner rates whether the candidate is able to recommend further imaging modalities to complete the diagnostic work-up and whether the candidate is familiar with clinical management issues. Of these two competences, at least one must be answered correctly. After considering all five tasks on the scoring sheet, the two examiners determine the final vote as "pass" or "fail." The candidates must pass all the individual clinical cases successfully to succeed in the oral part of the EDiMSK. In general, three clinical cases are planned for each candidate. Of note, all candidates consent on their application form that they understand that no appeal may be made related to the content of the examination.<sup>8</sup>

## Sample Cases for the Oral Part of the Examination

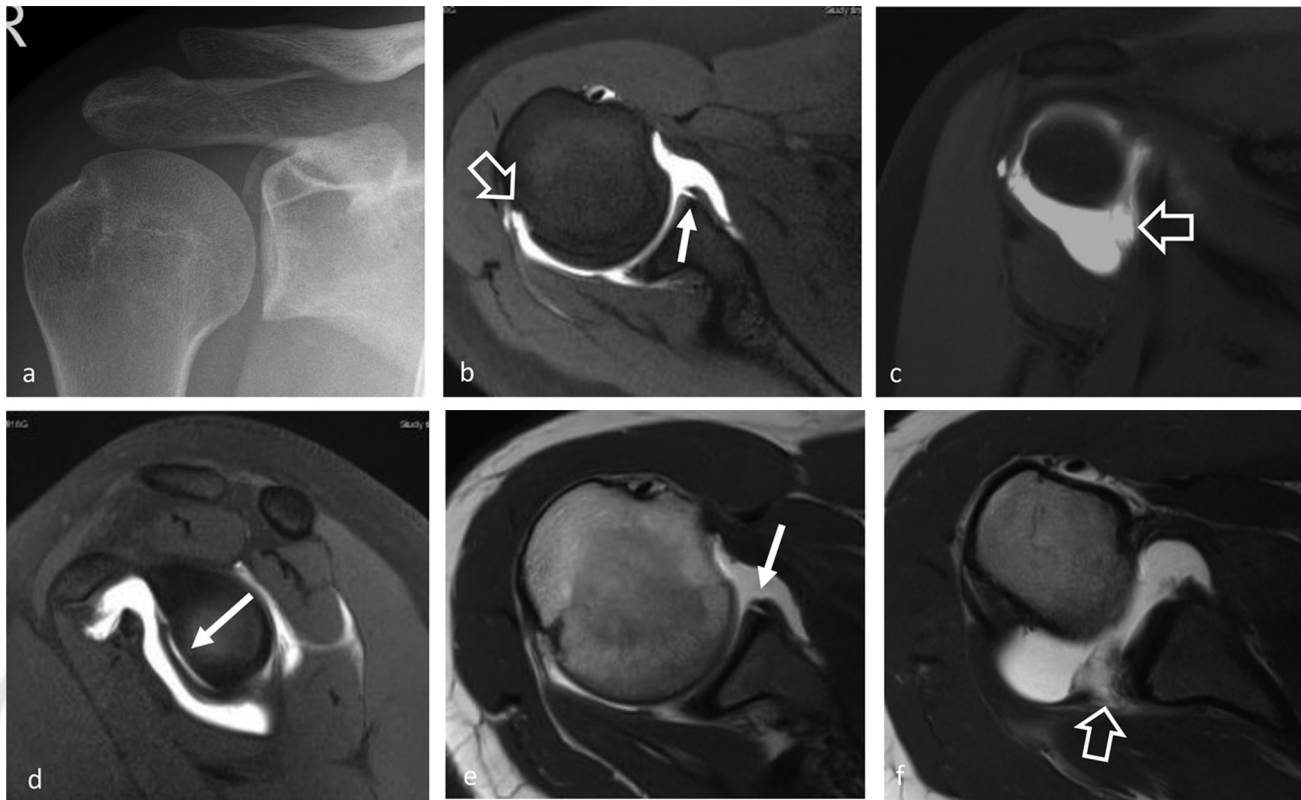
We present 10 cases that are representative of the oral part of the EDiMSK. Of note, in this article the images have been selected and pathologies are illustrated with arrows, making it much easier for readers to detect the pathology than for the actual exam candidate. The candidate must scroll through the whole series of images using the PACS workstation, and therefore the correct image illustrating the pathology has to be identified first.

### Case 1

*Clinical history:* An 18-year-old woman with recurrent shoulder dislocations.

These are the key points the candidate should address during the oral examination:

1. *Description of techniques available* (→ **Fig. 1**): The candidate should name and interpret the conventional radiograph of the right shoulder (a) and the magnetic resonance



**Fig. 1** (a) Conventional radiograph of the right shoulder. (b–f) Magnetic resonance arthrographic sequences of the right shoulder: T1-weighted sequences with fat suppression in three planes (b, axial; c, coronal, and d, sagittal; e, f, axial T1-weighted sequence at two positions). Arrows show the Perthes lesion: (b) open arrow at the Hill-Sachs defect and (c, f) open arrows at the glenoid avulsion of the glenohumeral ligament.

- (MR) arthrographic sequences of the right shoulder (b–f).
- Describe the findings of the first imaging test (i.e., the conventional radiograph of the right shoulder): No luxation of the glenohumeral joint.
  - Describe the findings of the second imaging test (i.e., the MR arthrogram): Impression of the posterolateral humeral head. Contrast interposition between the anterior and anteroinferior labrum and the glenoid. Avulsion of the glenohumeral ligament at the glenoid attachment.
  - Final/most likely diagnosis/differential diagnosis: Hill-Sachs defect, Perthes lesion, glenoid avulsion of the glenohumeral ligament.
  - What should be the treatment/management of this case? Surgical repair. In this patient, an open Latarjet was performed.<sup>10</sup>

The examiners then score with “yes” or “no” the answers to these questions: (1) Can the candidate recognize the

abnormalities? (2) Can the candidate interpret the abnormalities and arrive at a logical explanation? (3) Can the candidate determine the diagnosis or suggest a short differential? (4) Can the candidate recommend further imaging modalities to complete the diagnostic work-up? (5) Is the candidate familiar with the relevant clinical management issues?

## Case 2

**Clinical history:** A 23-year-old man. Acute twisting injury and knee pain.

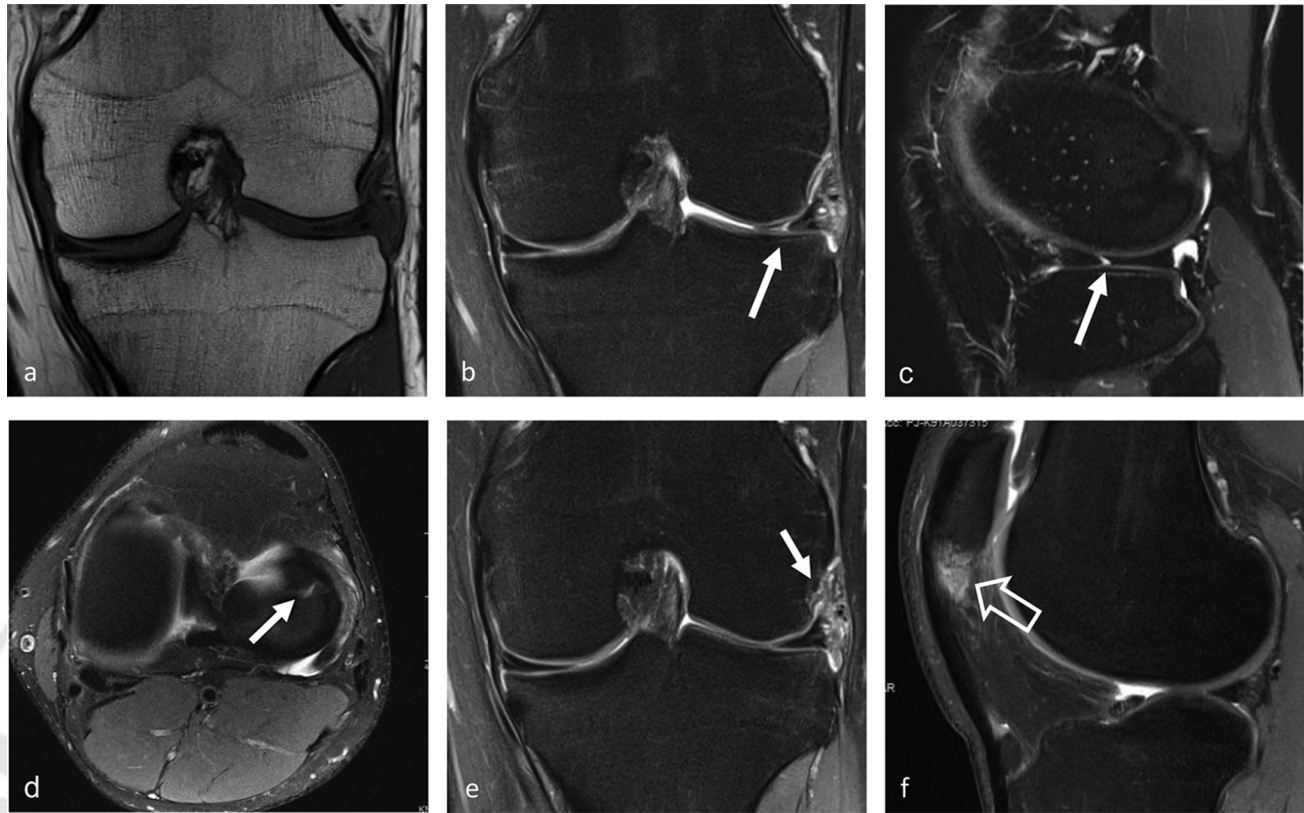
These are the key points the candidate should address during the oral examination in this case:

- Description of techniques available (– Fig. 2): The candidate should name the type of exam and the views available. In addition, the candidate should be familiar with the sequence weightings and should then interpret the MRI of the left knee.
- Describe the findings of the first imaging test (i.e., the MRI of the knee):

Normal to small effusion. Acute lateral radial meniscal tear in the anterior body. No displaced fragment. Adjacent meniscocapsular soft tissue injury with edema and hemorrhage adjacent to the anterior horn and body. However, the main ligamentous structures remain intact. Chronic-appearing mild to moderate central proximal patellar tendinopathy with reactive patellar bone marrow edema and cortical remodeling. No other active change in the remainder of the knee: medial meniscus, cruciate, and collateral ligaments. No acute osteochondral injury.

- Describe the findings of the second imaging test: Not available.
- Final/most likely diagnosis/differential diagnosis: Acute lateral meniscal tear and meniscocapsular injury.<sup>11</sup> Chronic patellar tendinopathy.
- What should be the treatment/management of this case? Surgery is necessary because of the acute lateral meniscal tear and the meniscocapsular injury. Physiotherapy is





**Fig. 2** Magnetic resonance image of left knee. (a) Coronal T1-weighted sequence. (b) Coronal proton-density fat-saturated sequence. (c) Sagittal T2-weighted fat-saturated sequence. (d) Axial proton-density fat-saturated sequence. (e) Coronal proton-density fat-saturated sequence. (f) Sagittal proton-density fat-saturated sequence. Arrows indicate the vertical tear of the lateral meniscus; the open arrow indicates the proximal patellar tendinopathy with reactive patellar bone marrow edema.

indicated for chronic patellar tendinopathy.

### Case 3

**Clinical history:** A 33-year-old man presenting with right-sided shoulder pain and an incidental finding on radiographs.

These are the key points the candidate should address during the oral examination in this case:

1. **Description of techniques available (–Fig. 3):** The candidate should name and interpret the radiograph of the right humerus (a), the MRI examination (b–d), the 18F-fluorodeoxyglucose (18F-FDG) positron emission tomography (PET) scan (e), and the computed tomography (CT) scan (f).
2. **Describe the findings of the first imaging test (i.e., radiograph):** Identify calcification partially superimposed by bone.
3. **Describe the findings of the second imaging test: periphery (i.e., MRI):**

High signal edema outside a hypointense rim and a central heterogeneous high T2 signal and contrast enhancement.

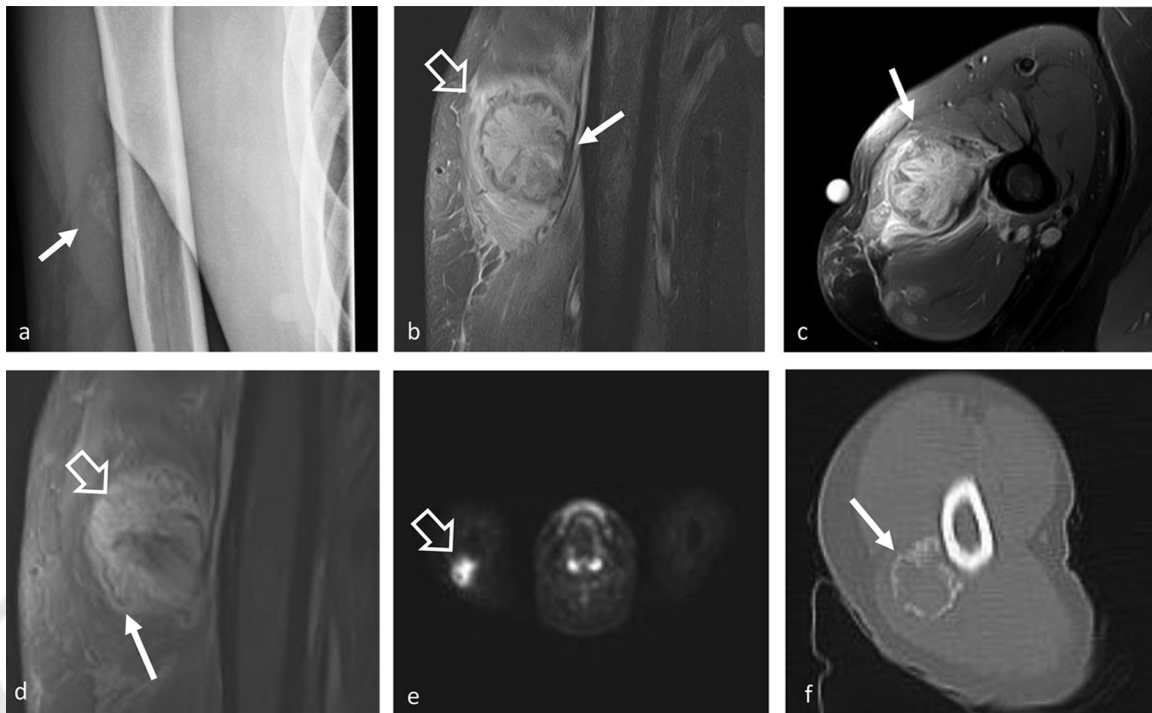
4. **Describe the findings of the third imaging test (i.e., PET):** Identify the avid FDG uptake of the lesion.
5. **Describe the findings of the fourth imaging test (i.e., CT):** Identify the peripheral rim of mineralization.
6. **Final/most likely diagnosis/differential diagnosis:** Myositis ossificans that was also proven at histology. Imaging differential considerations are parosteal osteosarcoma (that calcifies in the center and continues toward the periphery) and soft tissue sarcomas.
7. **What should be the treatment/management of this case?** Myositis ossificans is benign, and no compelling evidence indicates that malignant transformation ever occurs. Hence treatment is reserved for symptomatic lesions; surgical resection is usually curative.<sup>12</sup>

### Case 4

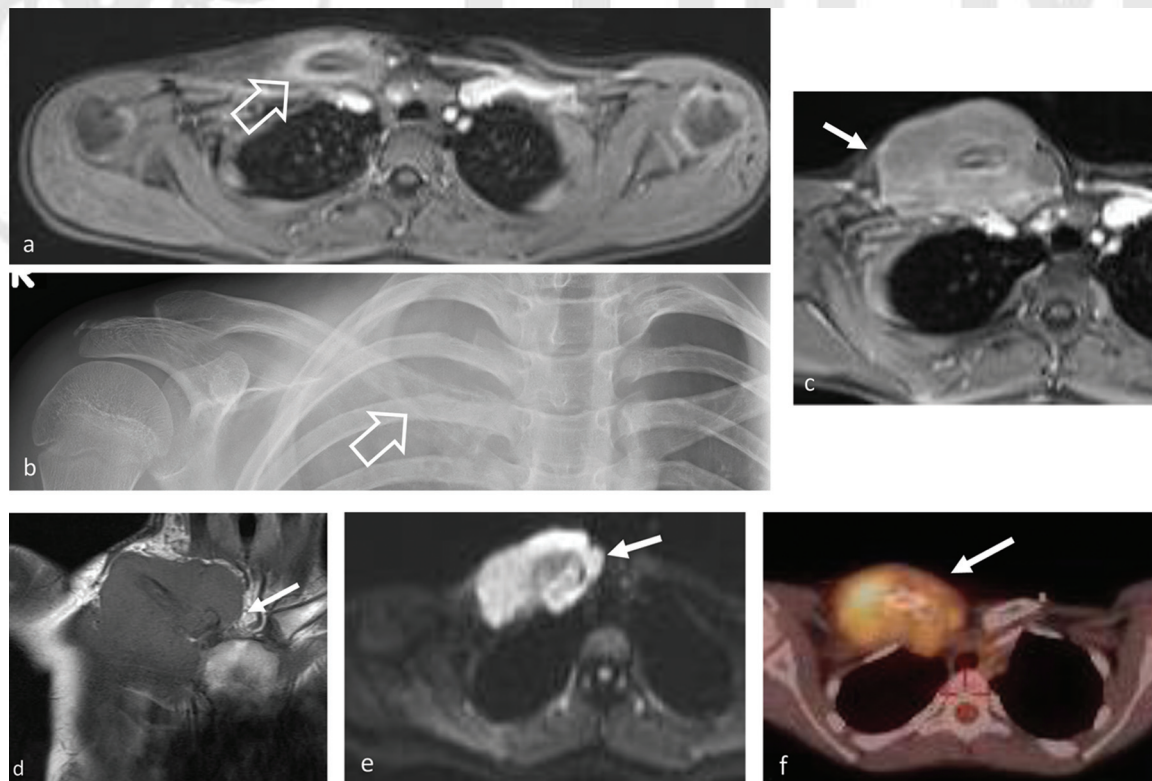
**Clinical history:** A 12-year-old girl with significant pain in the right clavicle for few days not responding to nonsteroidal anti-inflammatory drugs (NSAIDs). No fever, no trauma.

These are the key points the candidate should address during the oral examination in this case:

1. **Description of techniques available (–Fig. 4):** The candidate should name and interpret the initial MRI (a), the radiograph (b), as well as the follow-up MRI (c–e) and the 18F-FDG PET/CT fusion image (f).
2. **Describe the findings of the first imaging test (i.e., MRI):** Strong periosteal reaction of right clavicle.
3. **Describe the findings of the second imaging test (i.e., radiograph):** Osseous destruction of medial right clavicle.
4. **Describe the findings of the third imaging test (i.e., follow-up MRI):** Identify the large soft tissue component with restricted diffusion and

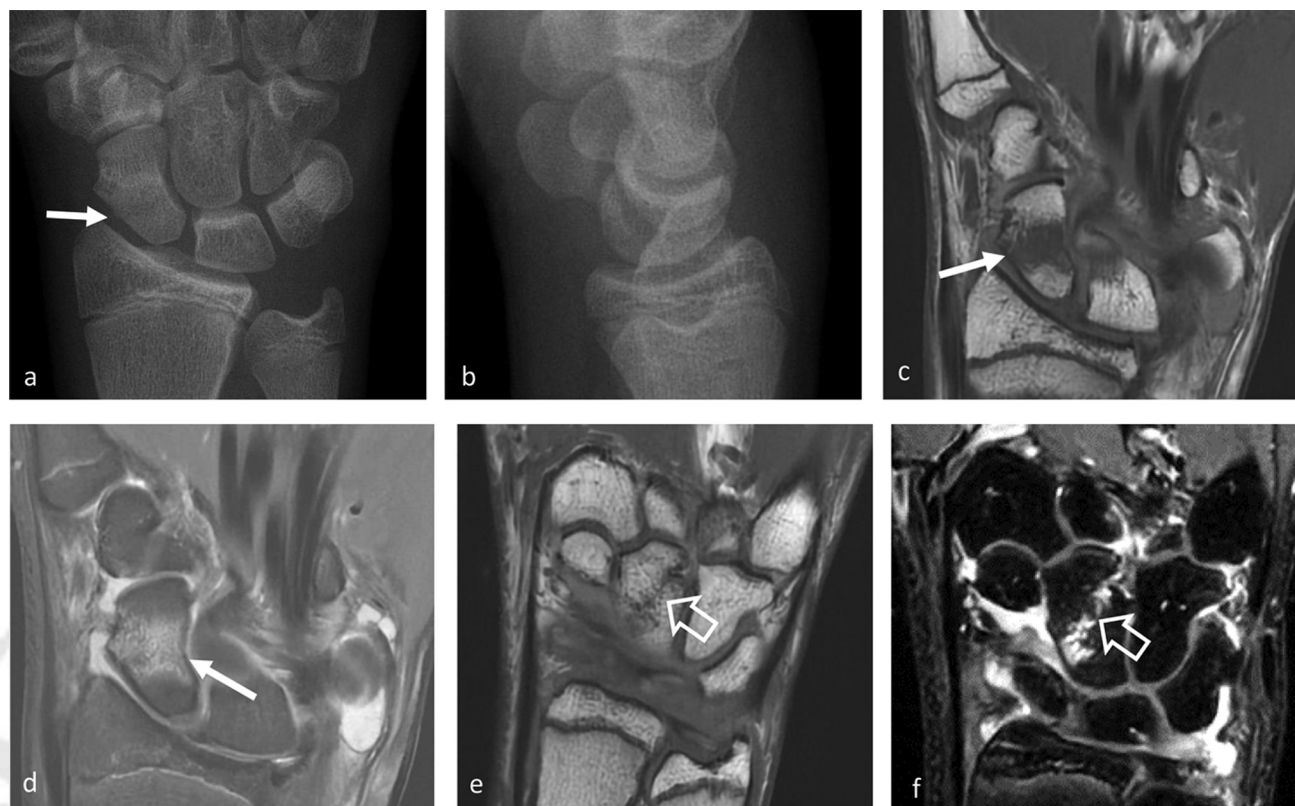


**Fig. 3** (a) Anteroposterior radiograph of right upper arm. (b) Coronal proton-density fat-saturated sequence. (c) Axial proton-density fat-saturated sequence. (d) Coronal contrast-enhanced T1-weighted fat-saturated sequence. (e) Axial 18F-fluorodeoxyglucose (FDG) positron emission tomography (PET) image. (f) Axial computed tomography. The arrow indicates the peripheral calcification (a, f) that appears (b) T2- and (d) T1-hypointense. Open arrow in (b) illustrates edema of the muscle tissue. Open arrow in (d) shows the contrast enhancement of the central part of the mass-lesion, and the open arrow in (e) points to the avid FDG uptake.



**Fig. 4** (a) Initial axial contrast-enhanced T1-weighted volumetric interpolated breath-hold examination (VIBE). (b) Radiograph of right clavicle 2 months later. (c) Axial contrast-enhanced T1-weighted VIBE 2 months after first magnetic resonance imaging. (d) Coronal T1-weighted sequence. (e) Axial diffusion-weighted image sequence (b-value: 600 s/mm<sup>2</sup>). (f) Axial 18F-fluorodeoxyglucose (FDG) positron emission tomography/computed tomography fusion. Open arrow in (a) points at the periosteal reaction and in (b) at the osseous destruction. (c–f) Arrows illustrate the soft tissue component with restricted diffusion (e) and avid FDG uptake (f).





**Fig. 5** (a) Radiograph anteroposterior view. (b) Radiograph lateral view. (c) Coronal T1-weighted sequence. (d) Coronal proton-density fat-saturated sequence. (e) Coronal T1-weighted sequence. (f) Coronal T2-weighted fat-saturated three-dimensional CUBE sequence. (a) Arrow indicates a break in the cortex of the scaphoid bone. (b, c) Arrows illustrate the bone marrow edema within the central part of the scaphoid bone. (e, f) Open arrows show the capitate bone also has a fracture line.

the cortical destruction of the right clavicle.

5. Describe the findings of the fourth imaging test (i.e., PET/CT): Identify the avid FDG uptake.
6. Final/most likely diagnosis/differential diagnosis: Ewing's sarcoma. A large soft tissue component is another characteristic feature, best depicted by MRI. After the first MRI, a chronic nonbacterial osteitis (CNO; previously called chronic recurrent multifocal osteomyelitis [CRMO]) was suspected. Therapy with indomethacin was started that alleviated the pain. The radiograph and the MRI 2 months later were performed because of progressive swelling of the right clavicle. Other differentials are osteosarcoma and osteomyelitis.
7. What should be the treatment/management of this case? Systemic chemotherapy is the mainstay of treatment with surgery and/or radiotherapy playing a role depending on the location and size of the tumor.<sup>13</sup>

#### Case 5

**Clinical history:** A 15-year-old boy after a fall from his bicycle.

These are the key points the candidate should address during the oral examination in this case:

1. Description of techniques available (►Fig. 5): The candidate should name and interpret the initial radiograph (a, b) and MRI performed 4 days later (c-f).
2. Describe the findings of the first imaging test (i.e., radiograph): Subtle crack of cortical bone of scaphoid.
3. Describe the findings of the second imaging test (i.e., MRI): Identify scaphoid and capitate fracture as well as the joint effusion.
4. Final/most likely diagnosis/differential diagnosis: Scaphoid fracture together with capitate fracture. Carpal fractures (incidence: 30–60 per 100,000 persons per year) are one of the more commonly overlooked fracture types.<sup>14</sup>

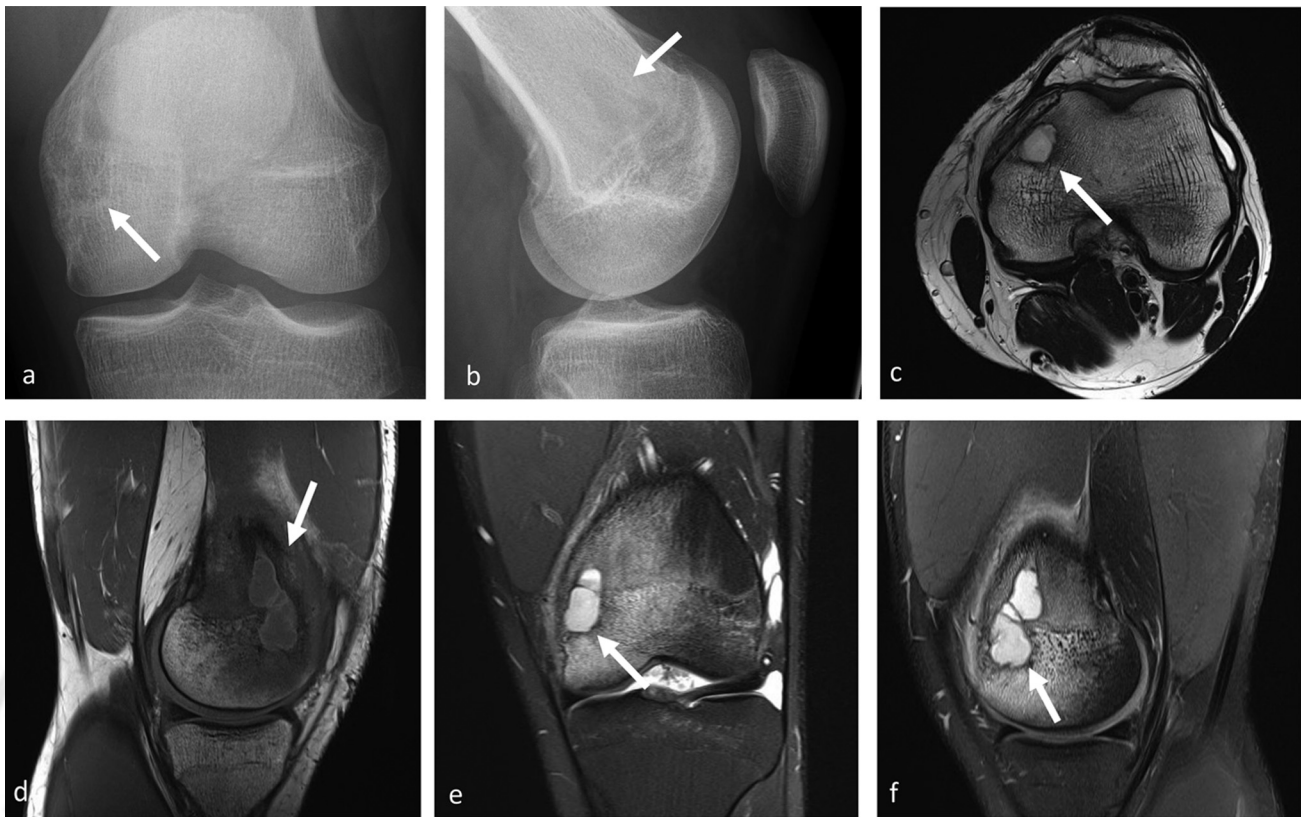
5. What should be the treatment/management of this case? Conservative therapy by immobilization in a scaphoid cast with thumb inclusion for 8 weeks.

#### Case 6

**Clinical history:** A 16-year-old boy who is an active basketball player. Acute pain at left knee previous night. No recent infection, no fever, no trauma.

These are the key points the candidate should address during the oral examination in this case:

1. Description of techniques available (►Fig. 6): The candidate should name and interpret the initial radiograph (a, b) and MRI performed 4 days later (c-f).
2. Describe the findings of the first imaging test (i.e., radiograph): Identify the lytic lesion in the typical oval configuration and in orientation along the long axis of the bone and surrounded by a reactive sclerosis.
3. Describe the findings of the second imaging test (i.e., MRI): Identify the



**Fig. 6** (a) Radiograph anteroposterior view. (b) Radiograph lateral view. (c) Axial T2-weighted sequence. (d) Sagittal T1-weighted sequence. (e) Coronal proton-density fat-saturated sequence. (f) Sagittal proton-density fat-saturated sequence. (a, b) Arrows indicate the osteolysis with a subtle sclerosing border. (c–f) Arrows illustrate the abscess formation within the epi-metaphyseal zone of the distal femur.

intraosseous abscess with the “penumbra sign” typical of subacute osteomyelitis (i.e., a rim lining of an abscess cavity with higher signal intensity than that of the main abscess on T1-weighted images).

4. *Final/most likely diagnosis/differential diagnosis:* Brodie’s abscess (*Staphylococcus aureus* was proven). The initial radiograph performed under the suspicion of a fracture was interpreted as uneventful. Differential diagnoses are osteoid osteoma and eosinophilic granuloma (focal form of Langerhans cell histiocytosis).
5. *What should be the treatment/management of this case?* Treatment consisted mostly of surgery followed by antibiotics; outcomes were generally reported as favorable.<sup>15</sup> In this case, abscess removal, curettage, and defect filling with allogeneic spongiosa and a cortico-cancellous chip was performed followed by systemic antibiotic therapy. Search for (other) infection focus revealed a large purulent pim-

ple that the patient had on his knee a few weeks earlier.

#### Case 7

*Clinical history:* A 60-year-old man with diabetes, ankle swelling, and redness.

These are the key points the candidate should address during the oral examination in this case:

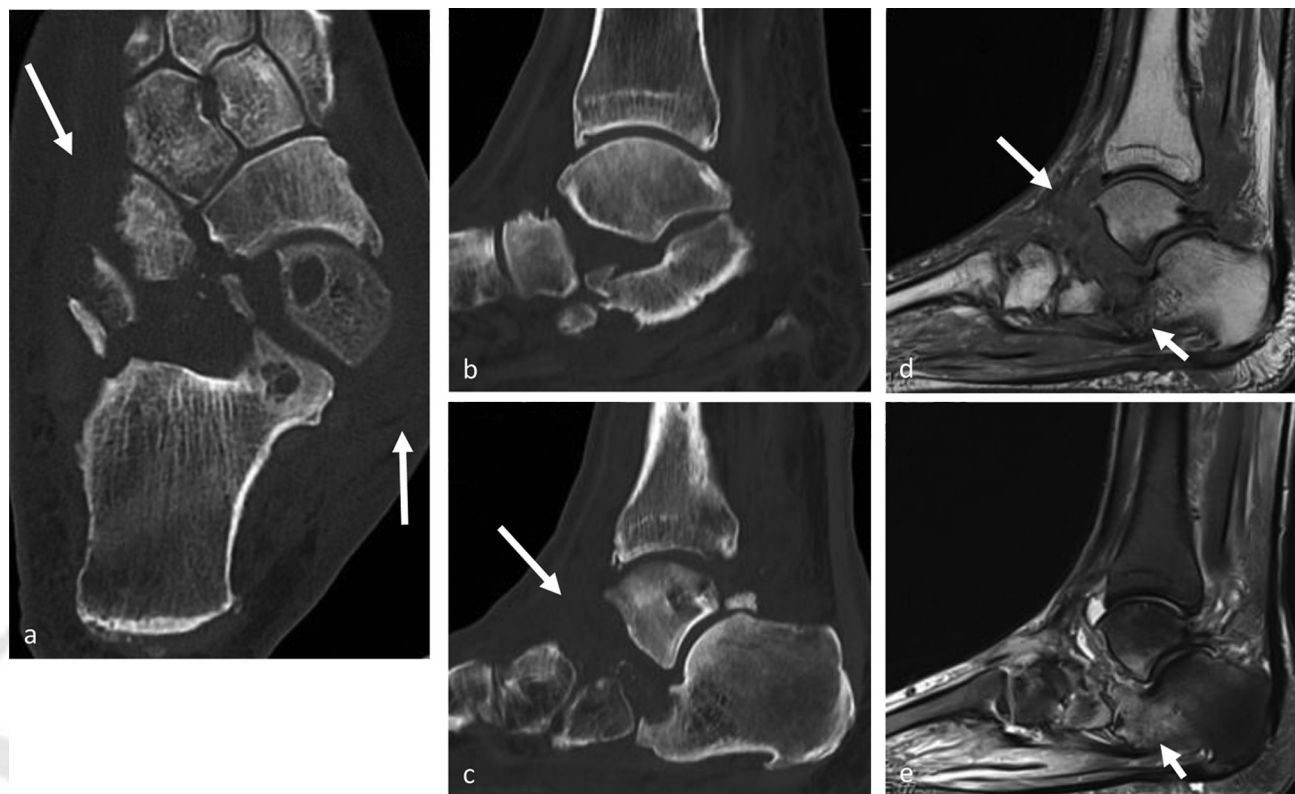
1. *Description of techniques available (→ Fig. 7):* The candidate should name and interpret the CT (a–c) and MR images (d, e).
2. *Describe the findings of the first imaging test (i.e., CT):* CT in axial (a) and sagittal (b, c) planes demonstrates dislocations and fragmentations of tarsal bones with soft tissue swelling.
3. *Describe the findings of the second imaging test (i.e., MRI):* T1-weighted (d) and short tau inversion recovery (STIR) (e) sagittal MRI additionally demonstrates bone marrow edema and soft tissue edema.

4. *Final/most likely diagnosis/differential diagnosis:* Charcot foot or Charcot joint, also known as a neuropathic joint or Charcot (neuro/osteoarthropathy) refers to a progressive degenerative/destructive joint disorder in patients with abnormal pain sensation and proprioception.

Imaging differential considerations are mainly advanced osteomyelitis that can coexist (especially in the foot) and can have a similar pattern of bone marrow signal on MRI.

5. *What should be the treatment/management of this case?* The careful choice of treatment is not only very important for the correct alignment of the foot and the loading capacity, but it also contributes significantly to the prevention of skin irritation or the healing of existing ulcers. Above all, chronic plantar ulcerations, caused by prominent exostoses or axial malalignments, are almost untreatable without surgery. Because diagnosis requires





**Fig. 7** Computed tomography in (a) axial and (b, c) sagittal reconstructions. (d) Sagittal T1-weighted and (e) short tau inversion recovery magnetic resonance images. (a–c) Arrows demonstrate the dislocations and fragmentations of tarsal bones with soft tissue swelling. (d, e) Short arrows illustrate the bone marrow edema; long arrow in (d) points to the adjacent soft tissue edema.

an individual approach, no strict regimen of therapy has been established.<sup>16</sup>

#### Case 8

**Clinical history:** An 11-year-old girl with a progressive, painless swelling of the medial side of the right clavicle. There are no systemic complaints; her previous medical history is unremarkable.<sup>17</sup>

These are the key points the candidate should address during the oral examination in this case:

1. **Description of techniques available (–Fig. 8):** The candidate should name and interpret the photograph (a), radiograph (b), CT (c), and MR images (d–f).
2. **Describe the findings of the first imaging test (i.e., radiograph):** Bone expansion at the medial side of the right clavicle. There is extensive bone sclerosis with a solid periosteal reaction.<sup>17</sup>
3. **Describe the findings of the second imaging test (i.e., CT):** Sclerotic

expansile lesion in the right medial clavicle.<sup>17</sup>

4. **Describe the findings of the third imaging test (i.e., MRI):** Hypointensity of the lesion compared with normal bone marrow on T1-weighted image (d) and hypointense signal compared with fluid on fat-suppressed T2-weighted image (e). Slightly heterogeneous enhancement on T1-weighted image after gadolinium contrast administration (f).<sup>17</sup>
5. **Final/most likely diagnosis/ differential diagnosis:** Chronic nonbacterial osteitis (CNO) (previously called chronic recurrent multifocal osteomyelitis [CRMO]). Differential diagnoses are numerous inflammatory, benign, and malignant bone diseases. Therefore, it is essential to know the diagnosis of CNO and to consider it in cases of an unclear inflammatory bone process in young patients.<sup>18</sup>
6. **What should be the treatment/management of this case?** CNO should be treated by a rheumatologist. Al-

though NSAIDs may offer some symptomatic relief, a greater degree of immunosuppression is often needed and possibly biologic agents.

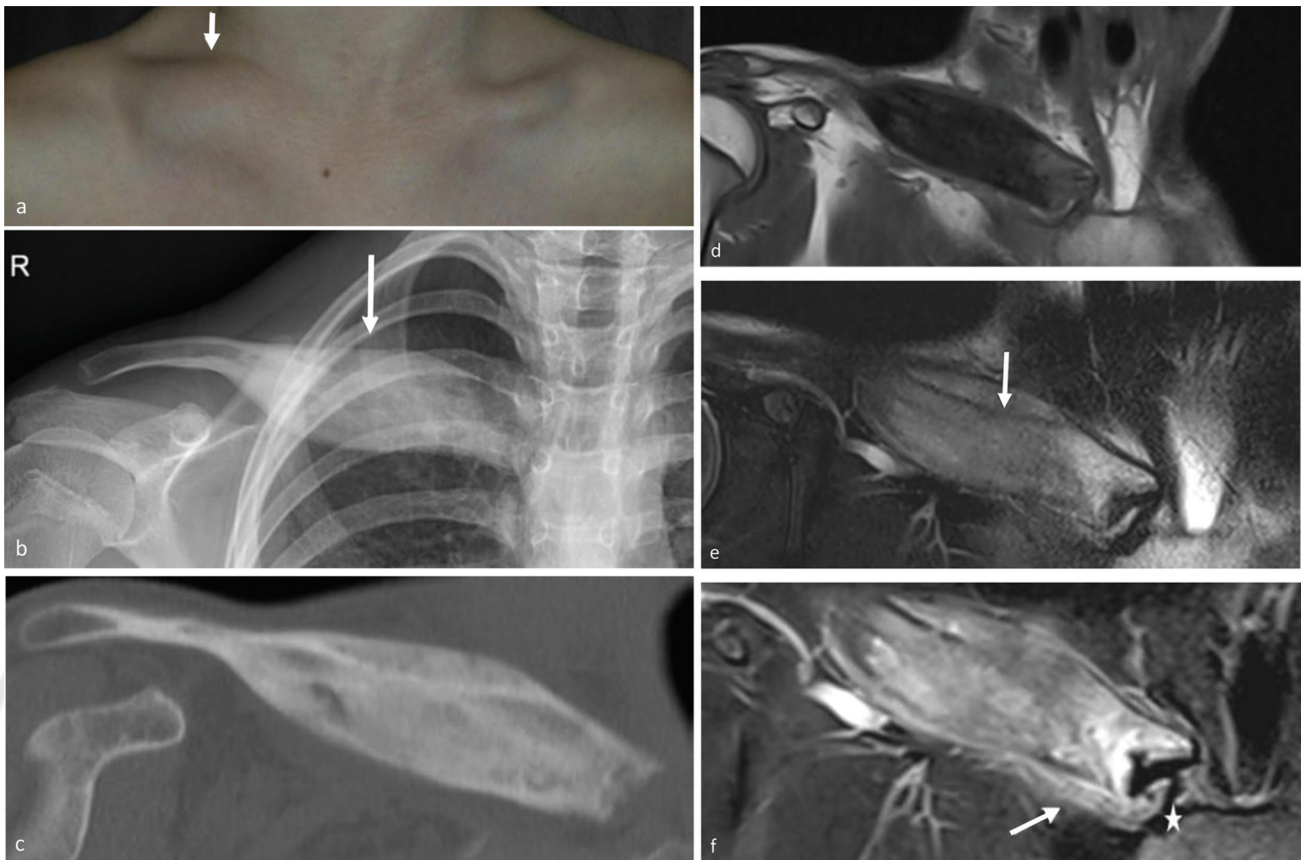
#### Case 9

**Clinical history:** A 15-year-old footballer with pain in the left groin.

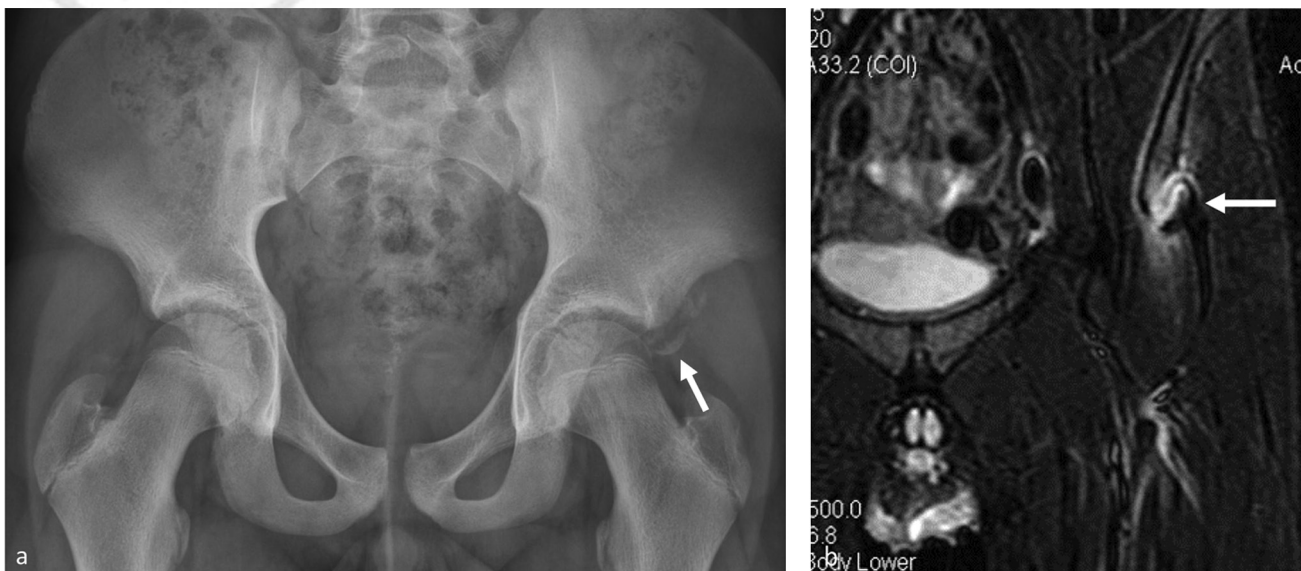
These are the key points the candidate should address during the oral examination in this case:

1. **Description of techniques available (–Fig. 9):** The candidate should name and interpret the radiograph (a) and the MR image (b).
2. **Describe the findings of the first imaging test (i.e., radiograph):** Identify the bony fragment near the left acetabular edge.
3. **Describe the findings of the second imaging test (i.e., MRI):** Identify the bony avulsion of the tendon of the direct head of the rectus femoris muscle.
4. **Final/most likely diagnosis/differential diagnosis:** Avulsion injury of spina iliaca anterior inferior (AIIS).

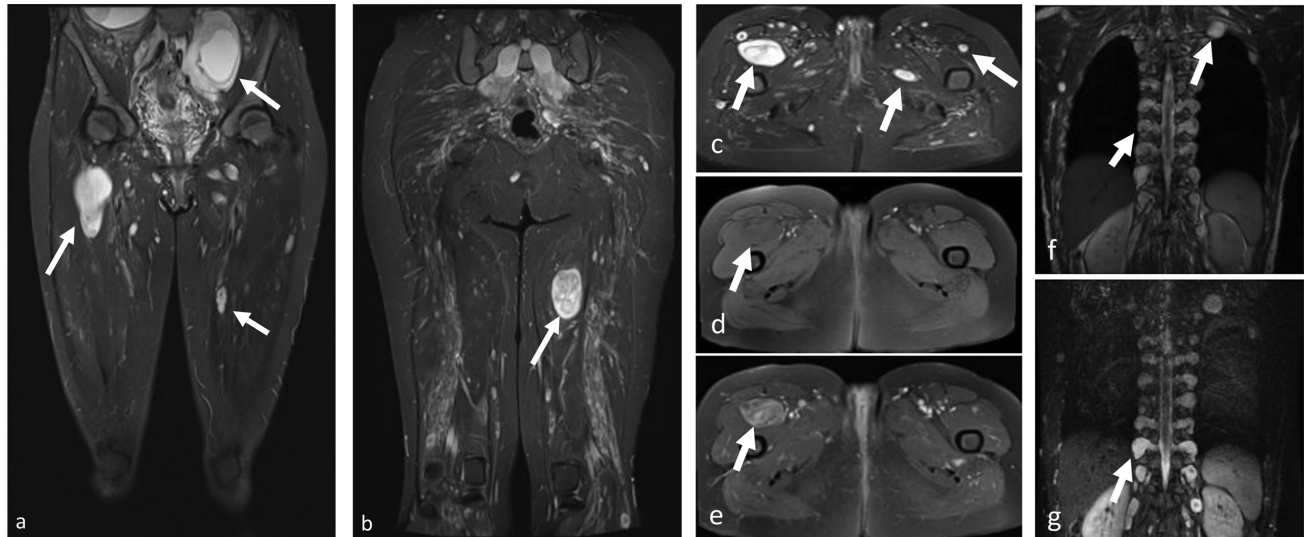




**Fig. 8** (a) Photograph, (b) radiograph, (c) computed tomography, and (d–f) magnetic resonance imaging of the clavicle. Bone expansion at the medial side of the right clavicle (a, b, arrows). There is extensive bone sclerosis with a solid periosteal reaction (b, c). Hypointensity of the lesion compared with normal bone marrow on T1-weighted image (d) and hypointense signal (arrow) compared with fluid on fat-suppressed T2-weighted image (e). Slightly heterogeneous enhancement on T1-weighted image after gadolinium contrast administration (f) within the affected part of the clavicle, which is most prominent adjacent to the sternoclavicular joint (asterisk). Note the subtle enhancement of the soft tissues adjacent to the clavicle (arrow).



**Fig. 9** (a) Plain radiograph of the pelvis. (b) Coronal short tau inversion recovery magnetic resonance imaging. Arrow in (a) demonstrates a bony fragment near the left acetabular edge and in (b) points to the bony avulsion of the tendon of the direct head of the rectus femoris muscle.



**Fig. 10** Both thighs. (a, b) Coronal proton-density fat-suppressed magnetic resonance images. (c) Axial proton-density fat-suppressed sequence. (d) Axial fat-suppressed T1-weighted sequence. (e) Contrast-enhanced T1-weighted fat-suppressed sequence. Thoracic spine. (f) Coronal T1-weighted image. (g) Coronal T2-weighted image. (a, b) Arrows indicate multiple masses in the pelvis along the course of the lumbar plexus and in both lower extremities along nerves. (c–e) Arrows demonstrate additional moderately enhancing masses along the several peripheral nerves. (f, g) Arrows illustrate bilaterally thickened spinal nerves exiting the neural foramina, as well as additional masses along the peripheral nerves.

An accurate and timely diagnosis is crucial when presented with these rare injuries to avoid increasing the chronicity of injury.<sup>19</sup>

5. *What should be the treatment/management of this case?* Because the fragment is not displaced to a major extent, conservative treatment is sufficient. Advise absence from sports for 8 weeks.

#### Case 10

**Clinical history:** A 38-year-old woman with multiple lumps and tingling sensations in lower extremities.

These are the key points the candidate should address during the oral examination in this case:

1. *Description of techniques available (►Fig. 10):* The candidate should name and interpret the MR images (a–g).
2. *Describe the findings of the first imaging test (i.e., MRI):* Identify the multiple masses in the pelvis along the course of the lumbar plexus and in both lower extremities along nerves. In addition, identify the moderately contrast-enhancing masses along several peripheral nerves and the bilaterally thickened spinal nerves exiting the neural foramina, as well as

additional masses along peripheral nerves.

3. *Describe the findings of the second imaging test:* Not available.
4. *Final/most likely diagnosis/differential diagnosis:* Neurofibromatosis. Neurofibromatoses comprise clinically and genetically distinct inherited conditions that carry a high risk of tumor formation. They fall under the wider classification of phakomatoses. The tumors particularly involve the central and peripheral nervous systems: neurofibromatosis type 1, neurofibromatosis type 2, and schwannomatosis.
5. *What should be the treatment/management of this case?* No single treatment exists, and a combination of supportive and surgical therapies are used, depending on the specific tumors and anomalies present. Although prognosis is very variable, overall life expectancy is approximately half that of nonaffected individuals. Tumors or cardiovascular complications are the most common causes of mortality.<sup>20</sup>

#### Conclusion

This article presented sample cases that make up the oral part of the EDiMSK exam, illustrating how the cases are structured and how exam-

iners score the candidate. We hope this article will help those who are preparing for the oral EDiMSK examination. Of course, these 10 sample cases will not be used in future EDiMSK examinations. Finally, something to smile about: Until now, no large language model tested (including ChatGPT 4) has been able to pass the EDiMSK examination.<sup>21</sup> We wish all candidates the best of luck!

#### Conflict of Interest

None declared.

#### Acknowledgments

Thanks very much to all members of the ESSR Educational Committee, the members of the external validation committee, the ESSR Executive Committee, all ESSR subcommittee chairs, and the ESSR office for their continuous support, enthusiasm, and time dedicated to the work of the ESSR Educational Committee.

#### References

- 1 European Society of Radiology. European Training Curriculum for Radiology. Available at: [https://www.myesr.org/app/uploads/2024/02/ESR\\_2024\\_European\\_Training\\_Curriculum\\_Level\\_III.pdf](https://www.myesr.org/app/uploads/2024/02/ESR_2024_European_Training_Curriculum_Level_III.pdf) Accessed June 23, 2024

- 2 European Society of Radiology. Education: advancing you. Available at: <https://www.myesr.org/education/> Accessed June 26, 2024
- 3 Council of European Specialist Medical Assessment. Available at: <https://www.uems.eu/areas-of-expertise/postgraduate-training/cesma>. Accessed June 25, 2024
- 4 Ruprecht M, Ricci P, Prosch H, Adriaensen MEAPM. Subspecialisation in radiology in Europe, a survey of the accreditation council of imaging. *Insights Imaging* 2023;14(01):159 Published correction appears in *Insights Imaging* 2023;14:192
- 5 Weber MA, Adriaensen M, Martinoli C et al. European Diploma in Musculoskeletal Radiology: written part of the exam. *Semin Musculoskelet Radiol* 2025;29(03):. Doi: 10.1055/s-0044-1793828
- 6 Snoj Ž, Hebar T, Sconfienza LM, et al. Present status of musculoskeletal radiology in Europe: international survey by the European Society of Musculoskeletal Radiology. *Semin Musculoskelet Radiol* 2020;24(03):323–330 Published correction appears in *Semin Musculoskelet Radiol* 2020;24:e1
- 7 Adriaensen M, Ruprecht M, Martinoli C, Vanhoenacker F, Robinson P, Drakonaki E. The European Diploma in Musculoskeletal Radiology: past, present, and future. *Semin Musculoskelet Radiol* 2024;28(03):352–355
- 8 European Society of Musculoskeletal Radiology. Diploma in Musculoskeletal Radiology. Available at: <https://www.essr.org/diploma/> Accessed June 23, 2024
- 9 Vanhoenacker F, Martinoli C. ESSR diploma: What's new? *J Belg Soc Radiol* 2017;101:1–2
- 10 Ladd LM, Crews M, Maertz NA. Glenohumeral joint instability: a review of anatomy, clinical presentation, and imaging. *Clin Sports Med* 2021;40(04):585–599
- 11 Griffith JF. Five overlooked injuries on knee MRI. *AJR Am J Roentgenol* 2021;217(05):1165–1174
- 12 Pătru S, Pădureanu V, Rădulescu D, et al. A nontraumatic myositis ossificans case of the forearm: case report and literature review. *Exp Ther Med* 2021;21(05):531
- 13 Weber MA, Papakonstantinou O, Nikodinovska VV, Vanhoenacker FM. Ewing's sarcoma and primary osseous lymphoma: spectrum of imaging appearances. *Semin Musculoskelet Radiol* 2019;23(01):36–57
- 14 Kussmaul AC, Kuehlein T, Langer MF, Ayache A, Löw S, Unglaub F. The conservative and operative treatment of carpal fractures. *Dtsch Arztebl Int* 2024 September 6 (Forthcoming:arztebl.m2024.0102)
- 15 van der Naald N, Smeeing DPJ, Houwert RM, Hietbrink F, Govaert GAM, van der Velde D. Brodie's abscess: a systematic review of reported cases. *J Bone Jt Infect* 2019;4(01):33–39
- 16 Hartig N, Krenn S, Trnka HJ. Surgical treatment of the Charcot foot: long-term results and systematic review [in German]. *Orthopade* 2015;44(01):14–24
- 17 Desimpel J, Vanhoenacker F. Chronic recurrent multifocal osteomyelitis (CRMO) of the clavicle. Available at: <https://www.eurorad.org/case/14212>. Accessed October 31, 2024
- 18 Heinrich A, Hauenstein C, Speth F, Weber MA. Chronic nonbacterial osteomyelitis: imaging and differential diagnoses [in German]. *Radiologe* 2020;60(09):863–876
- 19 Vadhera AS, Lee JS, Sivasundaram L, et al. Apophyseal ilium avulsion fractures in young athletes: a systematic review and return to sport analysis. *J Pediatr Orthop B* 2023;32(03):268–277
- 20 Di Pietro S, Reali L, Tona E, et al. Magnetic resonance imaging of central nervous system manifestations of type 1 neurofibromatosis: pictorial review and retrospective study of their frequency in a cohort of patients. *J Clin Med* 2024;13(11):3311
- 21 Gunes YC, Cesur T. Assessing the diagnostic performance of large language models with European Diploma in Musculoskeletal Radiology (EDiMSK) examination sample questions. *Jpn J Radiol* 2024;42(06):673–674